

Mandibular periosteal vertical distraction before dental implants placement: case report

Abstract

Periosteal Distraction (PD) has been investigated in animals for several years with the purpose of vertically bone augmentations in atrophic areas where osteogenic distraction (OD) is not possible. However, up to date, PD has not been related in humans. A 63-year-old woman, with vertical and transverse atrophy of the left inferior alveolar ridge, was clinically and tomographically assessed. A custom made periosteal distraction device (Tracper 3) was placed under local anesthesia. It was activated 0.25 mm every 12 hours since the fourth day, for 15 days. Four months later, a 7.5 mm vertical bone increase was tomographically confirmed. The PD device was then removed and two dental implants were placed and loaded three months later. This clinical case clearly shows the potential of the PD technique in severe bone atrophy in humans. More extensive clinical studies are necessary to confirm the interest and precise clinical modalities of utilization of periosteal distraction in humans.

Keywords: periosteal distraction, alveolar jaw bone atrophy, bone regeneration, dental implants.

Case Report

Volume 9 Issue 2 - 2018

Jorge Ivan Cardona Estrada,¹ Natalia Cardona Gómez,² Olga Celeny Becerra Herrera,³ Daniel Garcia Becerra,⁴ Jean Pierre Bernard DMD,⁵

¹Oral & Maxillofacial Surgeon, Private Practice, Colombia

²Oral & Maxillofacial Resident Surgeon, University of Antioquia, Colombia

³OCB Clinic, Manizales, Colombia.

⁴Dentist, Master in Laser-therapy, Clinica OCB, Manizales, Colombia

⁵Head for Education Swiss International Academy of Osseointegration, Switzerland

Correspondence: Jorge Ivan Cardona Estrada, Oral & Maxillofacial Surgeon, Private Practice, Pereira, Megacentro Pinares Torre 2 Office 809, Colombia, Tel +57 6 3212171, Email cirujano@jorgecardonamaxilofacial.com

Received: March 01, 2018 | **Published:** March 06, 2018

Introduction

Undifferentiated periosteal mesenchymal cells subjected to mechanical stress, can be transformed into osteoblasts and produce bone neo-formation in a similar way to what happens in osteogenic distraction where an osteotomy is performed followed by progressive separation of the bone fragments that generate new bone formation.^{1,2} This technique is today recognized as being effective to increase the vertical dimension of edentulous alveolar crests with severe atrophy.³ Studies on PD in experimental animals for over 22 years have combined several elements to promote neo-osteogenesis: tricalcium phosphate,⁴ RTG membranes,^{5,6} lipid-lowering drugs,⁷ plasma rich fibrin PRF⁸ and stem cells⁹ among others. According to Zhao and colleagues,¹⁰ it is now possible to start the clinical investigation of this technique.¹⁰ We conducted a preliminary study in humans, applying a subperiosteal distraction device to increase the height of the edentulous alveolar ridge allowing to place implants in the newly formed bone.

Clinical case presentation

A 63-year-old, non-smoker, female patient, with no relevant personal or family medical history, to whom two implants first right mandibular premolar and molar, had been placed six months previously, requested a similar treatment in the opposite side in the edentulous area distal to the first left mandibular premolar. The cone beam tomography (CB-CT) indicated a 10 mm alveolar height at level of the left second premolar with transversal deficiency and a 3.2 mm height at level the first left mandibular molar (Figure 1). The patient was informed of the necessity of a bone augmentation, with the possibility of utilization of heterologous or autologous bone graft or periosteal distraction, indicating her that this technique had

only been performed in experimental animal studies and explaining her the risks and benefits of each option. The patient agreed the PD option and signed the informed consent, authorized by the Medical Ethics of Human Research Committee at CES University of Medellin – Colombia. After dental impressions, an acrylic model was produce to prepare the distraction device. The CB-CT area was 3D printed at DME3D in Medellin - Colombia, eliminating the cortex in front of the inferior dental nerve, in such a way that the position of the nerve was clearly indicated (Figure 2).

For the PD, a prototype device called TRACPER 3 was used. It was designed from an alveolar osteogenic distractor (Walter Lorenz, Jacksonville-FL-USA), to which a 20 x 30 x 0.2 mm titanium mesh mm was fixed by means of a ligature wire, leaving it free to be adjusted and adapted to the edentulous bone morphology. Under appropriate aseptic measures, the distraction device was placed under loco-regional anesthesia with 2% lidocaine and epinephrine. An incision of the mucoperiosteum at the level of the jugal sulcus of the 35 to 38 area was performed, followed by subperiosteal dissection until visualization of the basilar edge of the jaw, of the complete alveolar crest in the lingual side of the mandibular body and of the left mental nerve. Multiple perforations of the alveolar bone surface where performed and the periosteal distraction device was fixed with four 1.5 mm titanium screws to the mandibular base (Figure 3). The mucoperiosteum was then incised and finally sutured in two layers with Polyglyd 5-0 resorbable material., and a radiographic control was performed (Figure 4). Amoxicillin 500 mg (Amoxal[®] Glaxo Wellcome Mayenne –France) 1 capsule every 8 hours for ten days and Nimesulide 100 mg (Mesulid[®] Novamed S.A Barranquilla – Colombia) 1 tablets every 12 hours for five days were given.. Four

days after placement the activation of the distraction device was initiated at a rate of 0.25 mm every 12 hours, after oral rinse during two minutes with 0.12% chlorhexidine digluconate (Clorhexol[®] Farpag Bogota – Colombia). At the time of activation, the integrity of the oral mucosa and dental occlusion was checked (Figure 5). A small mesio-lingual dehiscence in the 35 area in relation with the anterior edge of the titanium mesh was observed on the fourth day of activation. To manage this dehiscence a Triticum Vulgare phyto-stimulant (Fitostimuline Gel[®] Famaceutici Damor S.p.a Italy) was applied three times a day, the edge of the exposed mesh was cuted, and an acetate plate was placed to protect the left lateral side of the tongue. Distraction stage process was conducted on 15 days for a total of 30 activations, equivalent to 7.5 mm increase in alveolar height. Upon completion of the distraction, 12 daily sessions of intraoral 940 nm laser diode (Biolase, Cromwell, Irvine CA – US), were applied with 0.2 W/continuous mode (CW). The hand piece was positioned

at 8 mm from the mucosa moving the spot from mesial to distal of the PD area for 20 seconds on vestibular side and lingual side, in the goal to decrease the pain and inflammation of the ulceration that stay stable during the activation time. After the periosteal distraction, a CB-CT was performed to objective the result and to decide the length and diameter of the implants (Figure 6) (Figure 7). Removal of the periosteal distraction device and placement of the dental implants were carried out four months after the distraction. A fibrotic capsule was firmly attached to the device mesh (Figure 8). The clinically observed bone quality was favorable. The PD device was removed and two Bone Level implants NC Roxolid SLA (Straumann, Basel Switzerland) were placed, 3.3 x 8 mm for 35 and 4.1 x 10 mm for 36 (Figure 9). A sample of bone tissue was harvested in 37 area, for histological analysis (Figure 10). Following the conventional loading protocol¹¹ for osseointegration implant, 'prosthetic rehabilitation was performed 3 months after implants placement (Figure 11) (Figure 12).

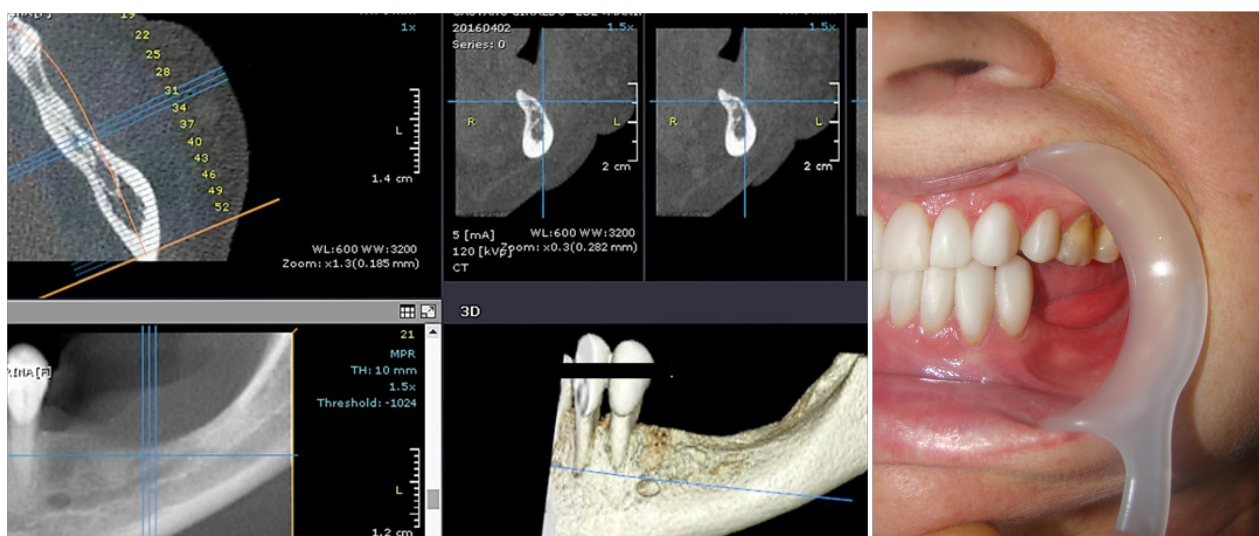

Figure 1 Presurgical aspect A: CB CT edentulous area; B: Height alveolar in 36 (3.2 mm).

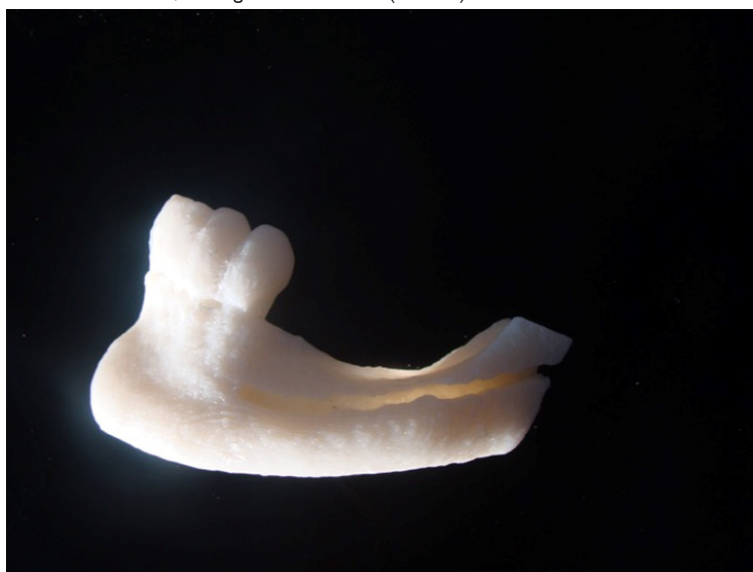

Figure 2 3D impression of the mandibular tomography.

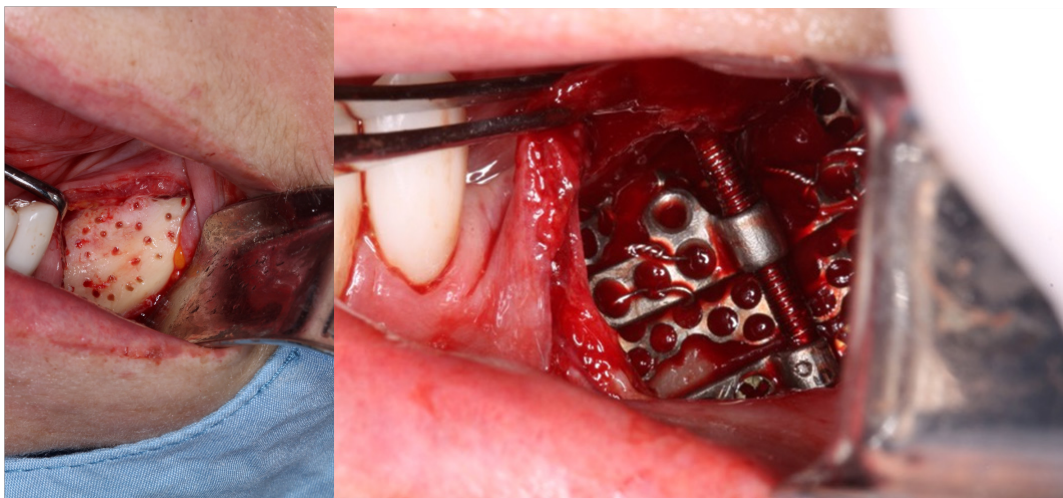


Figure 3 A: Multiple perforation of the alveolar cortex; B: Placement of the custom made distraction device with fixation to the basal mandibular edge.

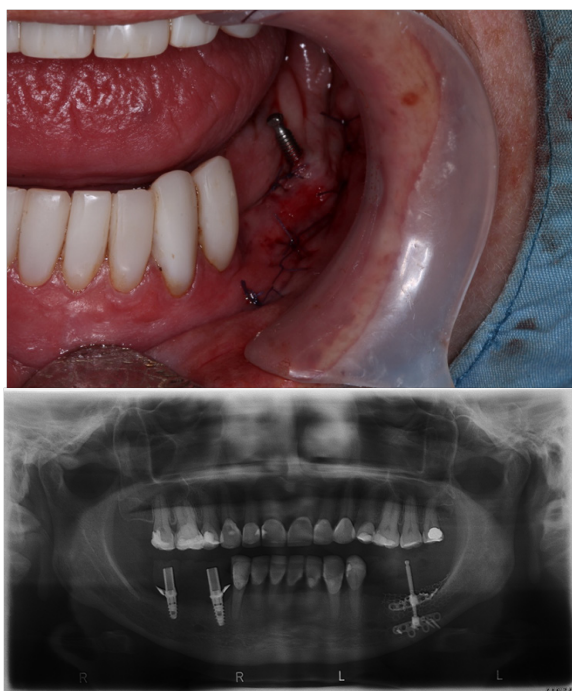

Figure 4 Clinical A: radiographic; B: position of the distraction device.

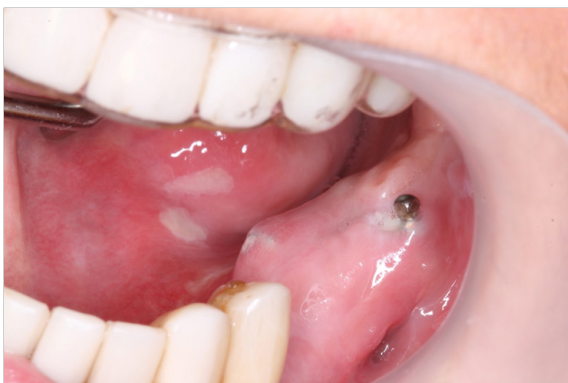
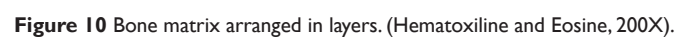
Figure 5 clinical views, on the 15th day of periosteal distraction

Discussion

Several studies advise the indication of alveolar OD when loss of height is greater than 7 mm (4.12); however, in places where due to anatomical limitations or with very severe alveolar atrophy as in the case presented, it is not possible to perform safely an osteotomy, PD could become the most appropriate choice. Despite being a custom made device, TRACPER 3 fulfilled the stated objective, with no micro-movements, which could affect the formation of bone callus.^{13,14} The design of this prototype should be improved and may motivate to design osteoinductive devices,¹⁵ or self-regulated⁵ or to combine them at the time of placement with biological elements.^{8,9} The titanium mesh in narrow areas could be the origin of mucoperiosteum ulcerations during the distraction process, so the mesh should be carefully adjusted during placement of the distraction device, in order to avoid high pressure at the periphery and angles of the mesh on the mucoperiosteal flap. A specifically designed prefabricated mesh would be an advantage in this field. Perforation of the cortical bone prior to the placement of the distraction device and preservation of the integrity of the periosteum are proposed in the literature, to improve the results.¹³⁻¹⁶ Despite differences between animal and human models,¹⁷ the periods of latency (4 days), distraction (15 days at a rate of 0.25 mm every 12 hours) and maturation (4 months prior to dental implant placement) were adequate for human application of the PD technique. Several scientific articles have reported that laser application¹⁸ accelerates bone mineralization, so it would be of interest to conduct comparative studies of PD with/without laser utilization to precise the ideal clinical protocol. Following the results obtained in human clinical studies with OD,¹⁹⁻²¹ a three months delay before loading the dental implants after the PD process, allowed to successful osseointegration and resistance to 35 ncm torque at the abutment placement. The bone specimen harvested 4 months after the periosteal distraction process from the new bone formed in our patient features the histologic characteristics of natural lamellar bone, and therefore the conditions to place implants. Kessler et al.²² found no significant differences in the type and quantity of bone obtained through subperiosteal technique and autologous bone graft in calvarium bone of pigs. In opposition to Sencimen et al.,³ they stated that the bone obtained allows the placement of dental implants after a consolidation period of only six weeks.

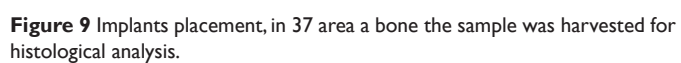
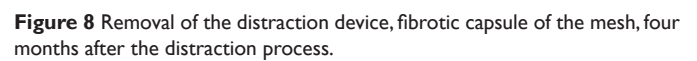
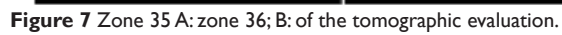
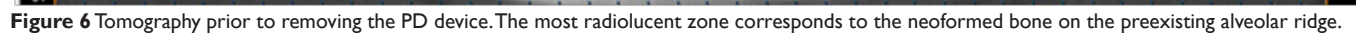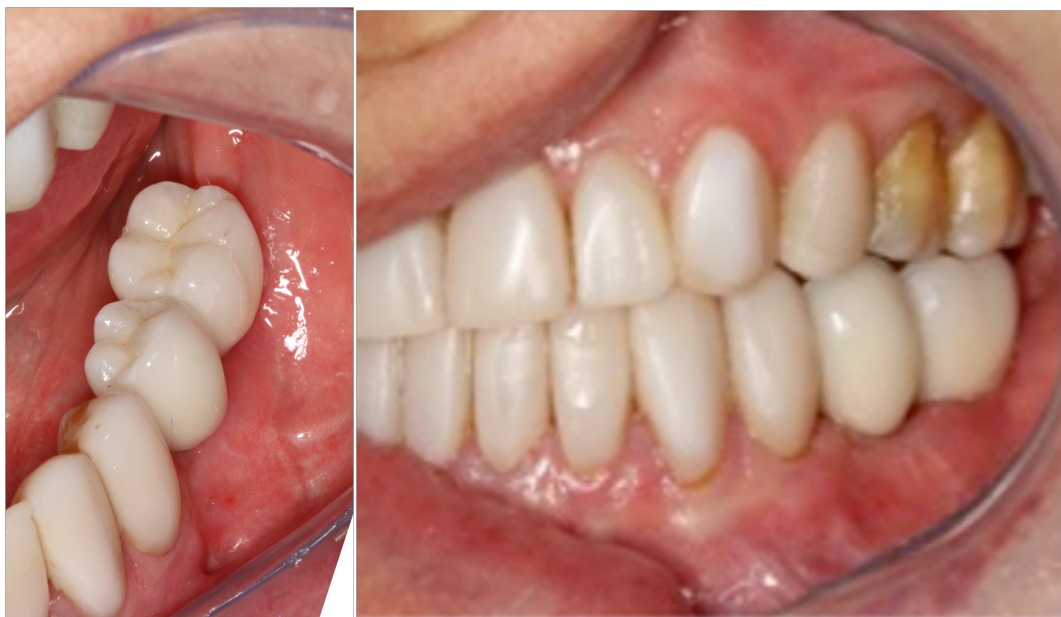




Figure 11 Implants 35 & 36 Final Rehabilitation three months later, A: coronal view; B: lateral view.

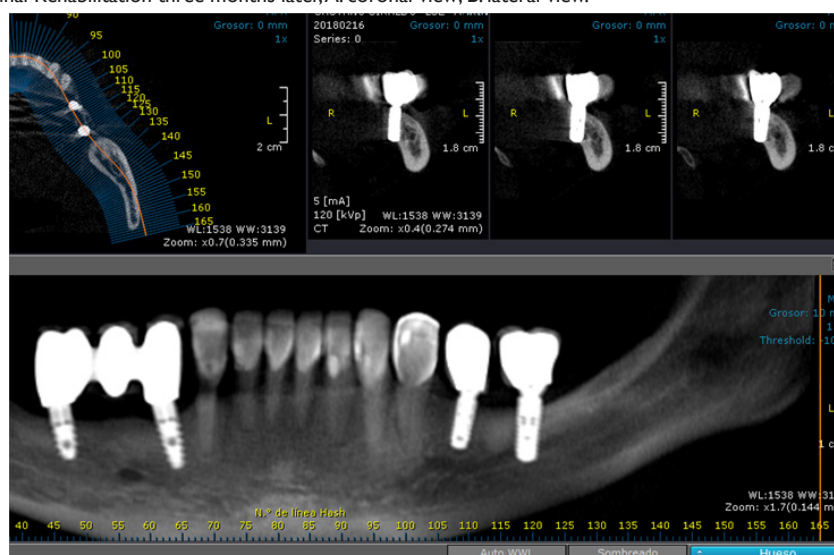


Figure 12 Final tomography.

Conclusion

Favorable preliminary results in this clinical case indicate that research carried out on animals has open the way to propose periosteal distraction in case of severe atrophy in edentulous areas for future implant placements in patients. Further human controlled clinical studies would be necessary to confirm, the potential of periosteal distraction in atrophic bone and to precise clinical modalities and timing to allow successful results for implants placed in the gained bone.

Acknowledgment

Thanks to Doctor Maria Eugenia Becerra Herrera for her invaluable cooperation in the preparation of the paper.

Conflict of interest

Authors state having no conflicts of interest.

References

1. Ozerdem OR, Kivanç O, Tuncer I, et al. Callotasis in nonvascularized periosteal bone grafts and the role of periosteum: a new contribution to the concept of distraction osteogenesis. *Ann Plast Surg.* 1998;41(2):148–55.
2. Delloye C, Delefortrie G, Coutelier L, et al. Bone regenerate formation in cortical bone during distraction lengthening. An experimental study. *Clin Orthop.* 1990;(250):34–42.
3. Sencimen M, Aydinoglu YS, Ortakoglu K, et al. Histomorphometrical analysis of new bone obtained by distraction osteogenesis and

- osteogenesis by periosteal distraction in rabbits. *Int J Oral Maxillofac Surg.* 2007;36(3):235–42.
4. Yamauchi K, Takahashi T, Funaki K, et al. Periosteal Expansion Osteogenesis Using Highly Purified Beta-Tricalcium Phosphate Blocks: A Pilot Study in Dogs. *J Periodontol.* 2008;79(6):999–1005.
 5. Yamauchi K, Nogami S, Martinez-de la Cruz G, et al. Timed-release system for periosteal expansion osteogenesis using NiTi mesh and absorbable material in the rabbit calvaria. *J Cranio-Maxillofac Surg.* 2016;44(9):1366–72.
 6. Saulacic N, Schaller B, Bosshardt DD, et al. Periosteal distraction osteogenesis and barrier membrane application: an experimental study in the rat calvaria. *J Periodontol.* 2012;83(6):757–65.
 7. Kahraman OE, Erdogan Ö, Namlı H, Sencar L. Effects of local simvastatin on periosteal distraction osteogenesis in rabbits. *Br J Oral Maxillofac Surg.* 2015;53(4):e18–22.
 8. Pripatnanont P, Balabid F, Pongpanich S, et al. Effect of osteogenic periosteal distraction by a modified Hyrax device with and without platelet-rich fibrin on bone formation in a rabbit model: a pilot study. *Int J Oral Maxillofac Surg.* 2015;44(5):656–63.
 9. Sato K, Haruyama N, Shimizu Y, et al. Osteogenesis by gradually expanding the interface between bone surface and periosteum enhanced by bone marrow stem cell administration in rabbits. *Oral Surg Oral Med Oral Pathol Oral Radiol Endod.* 2010;110(1):32–40.
 10. Zhao D, Wang Y, Han D. Periosteal Distraction Osteogenesis: An Effective Method for Bone Regeneration. *BioMed Res Int.* 2016;1–10.
 11. Gallucci GO, Morton D, Weber HP. Loading protocols for dental implants in edentulous patients. *Int J Oral Maxillofac Implants.* 2009;24 Suppl:132–46.
 12. Jensen SS, Terheyden H. Bone augmentation procedures in localized defects in the alveolar ridge: clinical results with different bone grafts and bone-substitute materials. *Int J Oral Maxillofac Implants.* 2009;24 Suppl:218–36.
 13. Sun Z, Herring SW. The effect of periosteal injury and masticatory micromovement on the healing of a mandibular distraction osteogenesis site. *Arch Oral Biol.* 2009;54(3):205–15.
 14. Estrada JIC, Saulacic N, Vazquez L, et al. Periosteal distraction osteogenesis: preliminary experimental evaluation in rabbits and dogs. *Br J Oral Maxillofac Surg.* 2007;45(5):402–5.
 15. Zakaria O, Madi M, Kasugai S. Induced osteogenesis using a new periosteal distractor. *J Oral Maxillofac Surg.* 2012;70(3):e225–234.
 16. Oda T, Kinoshita K, Ueda M. Effects of cortical bone perforation on periosteal distraction: an experimental study in the rabbit mandible. *J Oral Maxillofac Surg.* 2009;67(7):1478–85.
 17. Altuğ HA, Aydıntuğ YS, Sençimen M, et al. Histomorphometric analysis of different latency periods effect on new bone obtained by periosteal distraction: an experimental study in the rabbit model. *Oral Surg Oral Med Oral Pathol Oral Radiol Endod.* 2011;111(5):539–46.
 18. Abd-Elaal AZ, El-Mekawii HA, Saafan AM, et al. Evaluation of the effect of low-level diode laser therapy applied during the bone consolidation period following mandibular distraction osteogenesis in the human. *Int J Oral Maxillofac Surg.* 2015;44(8):989–97.
 19. Troulis MJ, Coppe C, O'Neill MJ, et al. Ultrasound: assessment of the distraction osteogenesis wound in patients undergoing mandibular lengthening. *J Oral Maxillofac Surg.* 2003;61(10):1144–9.
 20. Nocini PF, Albanese M, Wangerin K, et al. Distraction osteogenesis of the mandible: evaluation of callus distraction by B-scan ultrasonography. *J Craniomaxillofac Surg.* 2002;30(5):286–91.
 21. Chiapasco M, Zaniboni M, Rimondini L. Autogenous onlay bone grafts vs. alveolar distraction osteogenesis for the correction of vertically deficient edentulous ridges: a 2-4-year prospective study on humans. *Clin Oral Implants Res.* 2007;18(4):432–40.
 22. Kessler P, Bumiller L, Schlegel A, et al. Dynamic periosteal elevation. *Br J Oral Maxillofac Surg.* 2007;45(4):284–7.